

Original paper

# Efficacy and safety of percutaneous endobiliary radiofrequency ablation with a novel temperature-controlled catheter in malignant biliary strictures

Gulsah Yildirim<sup>A,B,C,D,E,F</sup>, Hakki Muammer Karakas<sup>A,B,E</sup>

Department of Radiology, Istanbul Fatih Sultan Mehmet Training and Research Hospital, University of Health Sciences, Turkey

## Abstract

**Purpose:** The purpose of this study is to evaluate the efficacy and safety of temperature-controlled endobiliary radiofrequency ablation (EB-RFA) followed by metal stent placement for nonresectable malignant biliary strictures.

**Material and methods:** From May 2017 to March 2021, 18 patients with malignant biliary obstruction who had undergone percutaneous EB-RFA and stent placement ( $n = 9$ ) or stent placement only ( $n = 9$ ) were included in this retrospective study. Outcomes were stent patency, technical and clinical success, overall survival, and 30-day complication rate. Kaplan-Meier and Cox regression analyses were performed to examine the relationship of EB-RFA with stent patency and overall survival.

**Results:** The clinical and technical success rate for each group was 100%. The median stent patency was 128 days (95% CI: 122.2-133.8) in the EB-RFA group and 86 days (95% CI: 1.2-170.7) in the control group. It was significantly longer in the study group ( $p = 0.012$ ). The mean overall survival was  $267.7 \pm 68.5$  days (95% CI: 133.3-402.2) in the study group and  $239.6 \pm 33.9$  days (95% CI: 173.1-306.2) in the control group. Log-rank test showed there was not a statistically significant difference in overall survival rates ( $p = 0.302$ ). There were no major complications and no statistically significant difference in cholangitis rates ( $p = 0.620$ ).

**Conclusions:** Percutaneous temperature-controlled EB-RFA combined with biliary stent placement for malignant biliary obstruction can be safe and feasible, and effectively increase stent patency.

**Key words:** malignant biliary obstruction, catheter ablation, radiofrequency ablation, stents, temperature, jaundice-obstructive.

## Introduction

Malignant bile duct obstructions (MBO) are usually associated with advanced stage tumoural pathologies (biliarypancreatic tumours, hepatocellular carcinoma, metastasis, etc.). In most cases, curative surgical treatment is not an option at the time of diagnosis, and biliary drainage is performed to palliate associated symptoms and decrease bilirubin levels to allow oncological treatment [1]. Biliary stents are safe and effective options to be used as a part of these pallia-

tive decompression interventions, and endobiliary stenting has become a standard procedure for symptomatic palliation of those who are unfit for surgery. Self-expandable metallic stents (SEMS) are the most commonly used method and provide longer patency than other biliary drainage devices [2]. However, even these stents may become occluded due to several factors [3]. Stent patency is a determinant of the cost-effectiveness of the procedure in these patients with low life expectancy and quality of life. In that context, endobiliary radiofrequency ablation (EB-RFA) is

## Correspondence address:

Gulsah Yildirim, Department of Radiology, Istanbul Fatih Sultan Mehmet Training and Research Hospital, University of Health Sciences, e-mail: [dr.gulsah.yildirim@gmail.com](mailto:dr.gulsah.yildirim@gmail.com)

## Authors' contribution:

A Study design · B Data collection · C Statistical analysis · D Data interpretation · E Manuscript preparation · F Literature search · G Funds collection

a novel and important adjunct to alleviate obstruction and to increase the efficacy of stents [4]. EB-RFA can be used prior to stent placement to provide longer patency. It has been proven to be a safe and effective method in cases with relatively rare complications [5,6]. Two types of EB-RFA systems have been developed: power- and temperature-controlled systems. Temperature-controlled catheters are relatively new and allow temperature monitoring during ablation [7]. Thus, complications related to thermal injury that may develop due to excessive energy can be prevented. This approach is relatively novel, and the number of published cases is still insufficient to determine the full value of percutaneous temperature-controlled EB-RFA regarding patency rates [8].

The purpose of this study was to evaluate the efficacy and safety of temperature-controlled EB-RFA followed by SEMS placement percutaneously in patients with non-resectable malignant biliary obstruction, compared with stenting alone.

## Material and methods

### Patient population and study design

The study was approved by the Institutional Review Board (approval no. 17073117\_050.06\_050.06 on 27.10.2020, 20202/11). Informed consent was obtained for the study and all patients were informed about the procedure.

The data of 18 patients who were diagnosed with malignant biliary obstruction and treated with SEMS w/o EB-RFA via percutaneous transhepatic approach were retrospectively reviewed. Nine patients who underwent metallic biliary stenting alone were selected as the control group (non-EB-RFA group). Nine patients treated with EB-RFA followed by metallic stenting were included in the study group (EB-RFA group). The pre-procedural evaluation of all patients was made by the oncologist and surgeon, and they were referred to interventional radiology. Before the procedure, all patients were evaluated clinically, biochemically (complete blood count, coagulation parameters, and blood biochemistry), and with imaging modalities (computed tomography, magnetic resonance imaging, ultrasound [US]).

These patients were enrolled between May 2017 and March 2021; all patients had clinical and laboratory findings of biliary obstruction at referral. Malignant biliary obstruction was caused by cholangiocarcinoma, pancreatic cancer, hepatocellular cancer, and metastasis. The criteria for inclusion in this study were as follows: (i) age > 20 years, histopathologically proven malignancy, (ii) clinical and laboratory findings for biliary obstruction, and (iii) surgically unresectable or medically unfit for surgery [9] with life expectancy more than 3 months. Exclusion criteria included uncorrectable coagulopathy (international normalized ratio > 1.5 or platelet count < 50,000 /mm<sup>3</sup>), clinical instability, surgical operability potential, and life

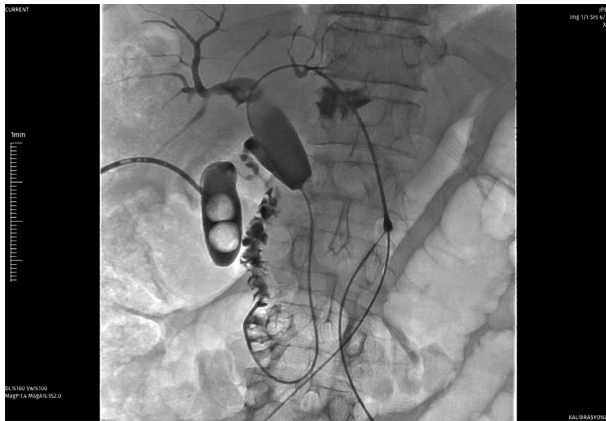expectancy less than 3 months. Endobiliary RFA stenting was preferred primarily in patients with a diagnosis of cholangiocarcinoma, considering the biliary ductal origin.

### Procedural steps

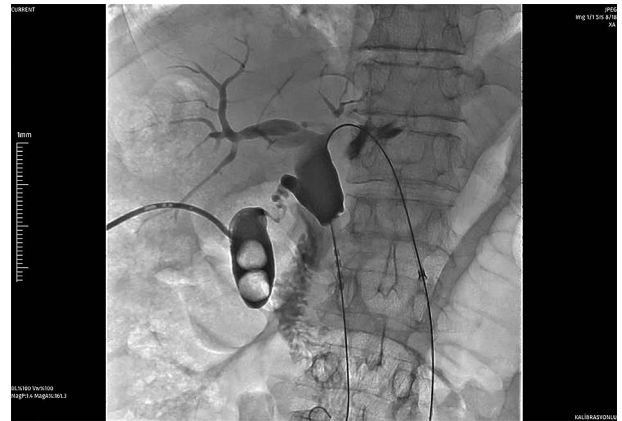All patients had percutaneous transhepatic cholangiography under fluoroscopy guidance to visualize the biliary tree and evaluate the location and length of the obstructed lumen a week before the stenting procedure. During the same session an 8F, 25 cm long internal-external biliary drainage catheter (Flexima APDL Catheter, Boston Scientific) was inserted for pre-procedural decompression and left in place for 48 to 72 hours until the treatment session.

In the study group, the stenting-ablation procedure was performed under general anaesthesia. A specifically designed temperature-controlled endobiliary RF catheter (ELRA, STARmed) and RF energy generator (VIVA combo RF Generator System, STARmed) were used for ablation. The bipolar electrodes at the terminal portion of the catheter were stainless steel rings (3 mm in width and 18 mm in length) connected to an RF energy generator. After the RF catheter was inserted above the 0.035-inch stiff guidewire, radio-opaque rings were positioned fully across the obstruction. This system operates in temperature mode, which enables continuous maintenance of the chosen electrode temperature during the RF procedure so that excessive heating is avoided. Each ablation procedure was performed at 10 W for 120 s, and the target temperature was set to 80°C. The ablation was started at the distal part of the stricture. Consecutive ablations were performed on strictures longer than the length of the ablation zone of the RFA probe. The RFA probe was removed after ablation and cholangiogram was immediately performed to rule out thermal injury-related complications such as bleeding or perforation. Afterward, balloon dilatation (Powerflex Balloon Catheter, Cordis) was applied up to the original size of the lumen to remove the intraluminal necrotic tissue. Following balloon dilatation, SEMS (Wallstent, Boston Scientific) with appropriate size (4-12 cm) and diameter (4-12 mm) were inserted in the study group. Following the stent placement, a control cholangiogram was performed to check whether the stent was opened sufficiently, and if necessary, balloon dilation was performed after the procedure (Figures 1-5). The diameters of the stenotic segments before and after the procedure were measured and recorded on fluoroscopy images. An 8 F internal biliary drainage safety catheter was placed over the guidewire and left closed. The safety catheter was then removed a week later after confirming the presence of adequate patency on the control cholangiogram. In patients with tumours involving bilateral hepatic biliary ducts, all procedural steps were repeated on each side and more than one stent was implanted.

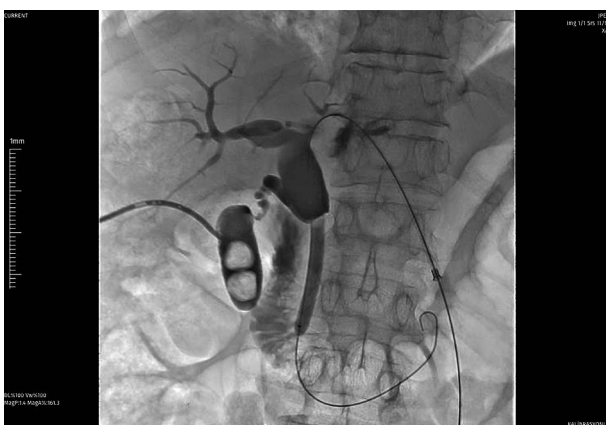In the control group, SEMS were inserted at the stricture level with the same stent placement protocol (size



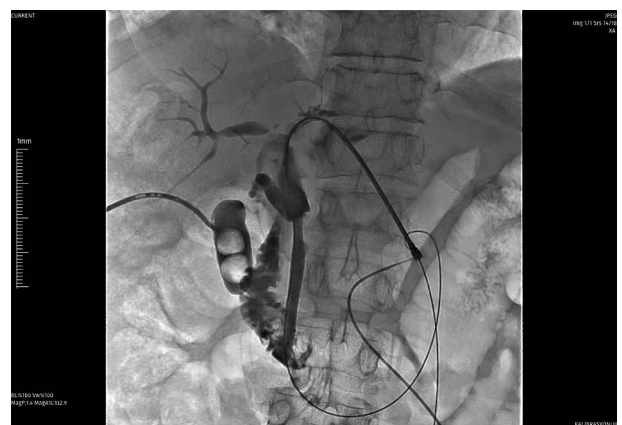**Figure 1.** 73-year-old male patient with a diagnosis of pancreatic head cancer (adenocarcinoma). Cholangiography before the procedure showed occlusion of the common bile duct



**Figure 2.** Radiofrequency ablation was performed to the distal common hepatic duct at 10 W



**Figure 3.** After the ablation balloon dilatation was applied at 12 atm to remove the intra-luminal necrotic tissue



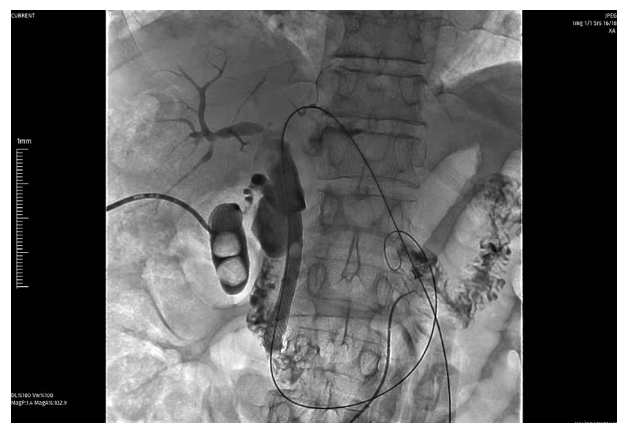
**Figure 4.** Self-expanding metallic stent (SEMS) was inserted over the 0.035-inch guidewire, and control cholangiography showed contrast passage

[4-8 cm] and diameter [6-10 mm]) as the study group. In the same way, an 8F biliary drainage catheter was inserted for control cholangiography and removed after the demonstration of free bile flow. First-generation cephalosporine (Cefazoline, 1 g IV) prophylaxis was administered to all patients periprocedurally.

### Post-procedural follow-up

In the EB-RFA group, patients were followed up overnight in the hospital, and the non-EB-RFA group was discharged on the same day as the procedure. They were re-examined for clinical success and short-term complications regarding remission of jaundice, biochemical tests, and US findings at the end of the first week. The safety catheter was also removed at the end of the first week following the demonstration of bile flow under fluoroscopy.

Stent patency and patient survival were followed up at regular intervals (first month, third month, and at three-month intervals). When laboratory parameters or clinical findings suggested cholestasis or cholangitis, patients were checked with fluoroscopy for suspected stent occlusion. Patients who were found to have insufficient



**Figure 5.** Following the stenting, balloon dilatation was performed to open the stent sufficiently

patency or stent occlusion during follow-up were further treated with RF ablation, balloon dilatation and/or biliary drainage catheter insertion, or second stent placement as appropriate.

The primary outcome of this study was safety and stent patency. Stent patency time was defined as the interval between the first stent placement and the recurrence of obstruction symptoms. The secondary endpoints were

overall survival, technical and clinical success, and complication rate. Overall survival was calculated as the time from the first stenting to the last follow-up or death. Technical success was defined as the placement of the stent in the appropriate position and subsequent biliary drainage. Clinical success was defined as an improvement of clinical symptoms of biliary obstruction and a decrease in serum total bilirubin levels of more than 25% of the initial value [10]. Procedure-related complications were defined according to the clinical practice guidelines of the Society of Interventional Radiology Standards of Practice Committee [11].

## Results

Of the 18 patients, 15 (83.3%) were men and 3 (16.6%) were women. The RF ablation and control groups were closely matched in terms of age, gender, and co-therapy regimen ( $p > 0.05$ ). Patient demographic data and clinical features are summarized comparatively in Table 1. Clinical success was achieved in all patients. The EB-RFA and stenting procedure was technically successful in all patients. For patients in the study group who were diagnosed with klatskin tumour, EB-RFA was performed in 3 different localizations, right, left, and main hepatic duct, and they underwent bilateral stenting. Additionally, 2 patients from the control group underwent bilateral stenting.

In the study group, the mean pre-ablation luminal diameter was  $2.3 \pm 1.1$  mm (range: 1.0-3.5 mm) and the mean post-ablation luminal diameter was  $7.9 \pm 2.1$  mm (range: 5.0-11.0 mm). In the control group, the mean pre-ablation

luminal diameter was  $1.1 \pm 0.9$  mm (range: 0-1.2 mm), and the mean post-ablation luminal diameter was  $5.5 \pm 1.6$  mm (range: 3.5-7.0 mm). There was a statistically significant difference between the groups for pre-procedural ( $p = 0.011$ ) and post-procedural luminal diameter ( $p = 0.20$ ). Stent patency was calculated as the time from the day the stent was inserted to the day that occlusion was proven or the patient died. In the study group, the median stent patency was 128 days (95% CI: 122.2-133.8), and in the control group it was 86 days (95% CI: 1.2-170.7). It was significantly longer in the EB-RFA group ( $p = 0.012$ ). Stent patency curves according to Kaplan-Meier analysis are shown in Figure 6. Although the stent patency in each group was comparable to that reported in previous studies, a difference was found in the mean luminal diameter before and after the procedure because patients in our study had a variety of stenosis sites.

Clinically, jaundice was resolved in all cases at the end of the first week following the procedure. The pre-procedural total bilirubin level was  $8.75 \pm 4.26$  mmol/l in the study group and  $5.73 \pm 5.22$  mmol/l in the control group. The direct bilirubin level was  $6.82 \pm 3.34$  mmol/l in the study group and  $4.53 \pm 4.34$  mmol/l in the control group. The post-procedural total bilirubin level on the 7<sup>th</sup> day was  $3.83 \pm 2.61$  mmol/l in the study group and  $2.84 \pm 2.77$  mmol/l in the control group, and direct bilirubin level was  $2.78 \pm 1.99$  mmol/l in the study group and  $1.36 \pm 1.29$  mmol/l in the control group. The difference in total ( $p = 0.01$ ) and direct bilirubin ( $p = 0.00$ ) levels was statistically significant in both groups. Clinical success was not significantly different between the groups. Procedural results are summarized in Table 2.

**Table 1.** Demographic and baseline clinical characteristics of patients

Factor	EB-RFA-stent group	Stent group	<i>p</i> -value
Age (years), mean $\pm$ SD	61.7 $\pm$ 4.5	55.1 $\pm$ 3.5	0.266
Gender, <i>n</i> (%)			
Female	1 (11.1)	2 (22.2)	0.555
Male	8 (88.9)	7 (77.8)	
Aetiology, <i>n</i> (%)			
Cholangiocarcinoma	6 (66.7)	2 (22.2)	0.046
Metastasis	2 (22.2)	2 (22.2)	
Hepatocellular carcinoma	1 (11.1)	–	
Pancreatic adenocarcinoma	–	5 (55.6)	
Bilirubin (mmol/l) at diagnosis, mean $\pm$ SD	TB: 8.75 $\pm$ 4.26; DB: 6.82 $\pm$ 3.45	TB: 5.73 $\pm$ 5.22; DB: 4.53 $\pm$ 4.34	0.492; 0.130
Chemotherapy, <i>n</i> (%)	6 (66.7)	8 (88.9)	0.000
Level of obstruction, <i>n</i> (%)			
Hilar	2 (22.2)	2 (22.2)	0.865
Proximal	1 (11.1)	2 (22.2)	
Distal	6 (66.7)	5 (55.6)	

SD – standard deviation, EB-RFA – endobiliary radiofrequency ablation.  
 $P > 0.05$  means there is no difference between the groups.



In both groups, no procedure-related major complications such as bile duct perforation, peribiliary sepsis, haemorrhage, or pancreatitis were observed. Six patients (4 [44.4%]: study group, 2 [22.2%]: control group,  $p = 0.620$ ) experienced cholangitis within the first week and were successfully treated with antibiotherapy. Six patients (3 [33.3%]: study group, 3 [33.3%]: control group) had abdominal pain after the procedure; all of them responded to analgesic therapy. No late (7-30 days) complications were reported in either group.

The mean follow-up time was  $211.4 \pm 144.3$  days (range, 81-558 days) in the study group and  $192.8 \pm 83.4$  days (range, 66-310 days) in the control group. Data analyses were performed at 6 months of follow-up. At the end of this period, 5 patients (55.5%) in the study group and 3 patients (33%) in the control group had died. Survival curves according to Kaplan-Meier analysis are shown in Figure 7. The log-rank test showed there was no statistically significant difference in overall survival rates between the study group and the control group ( $p = 0.302$ ). The mean survival was  $267.7 \pm 68.5$  days (95% CI: 133.3-402.2) in the study group and  $239.6 \pm 33.9$  days (95% CI: 173.1-306.2) in the control group.

Patients with stent occlusion during follow-up were further treated with RF ablation (2 in the study group), balloon dilatation (7 in the study group, 5 in the control group), and biliary drainage catheter insertion (all patients). Additional stenting was required in 2 patients (1 in the study group, 1 in the control group).

## Discussion

In patients with malignant biliary obstruction, surgical resection remains the only treatment method for cure. Even with surgical treatment, the 5-year overall survival rate is between 18% and 35% [12]. Most patients with MBO are found have locally advanced stage or metastatic disease. In these patients, palliative interventions to establish and preserve adequate biliary drainage are necessary to prolong survival and to increase the quality of life [13]. In that

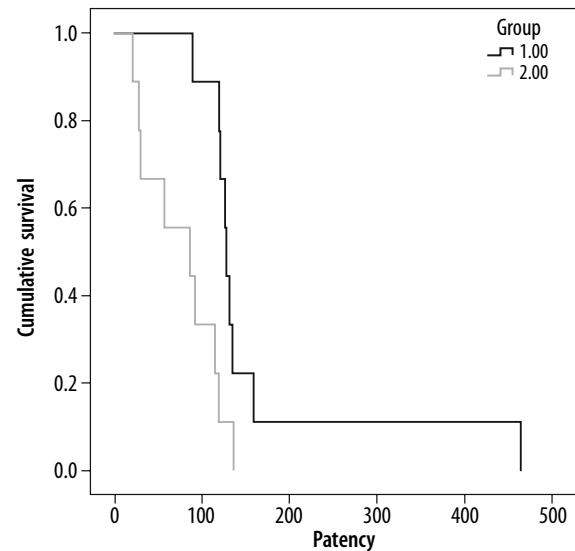


Figure 6. Patency comparison with Kaplan-Meier analyses. Curves showing a significant difference in stent patency time between the EB-RFA group and the control group (patency – stent patency)

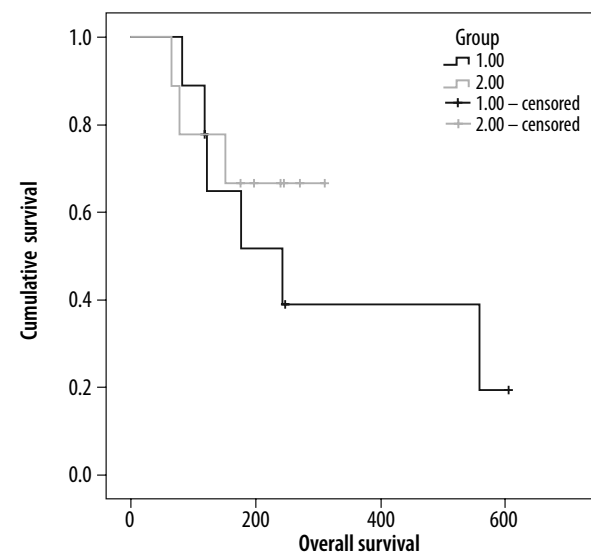


Figure 7. Survival comparison with Kaplan-Meier analyses revealed no difference in survival between the EB-RFA group and the control group

Table 2. Comparison of outcome

Variables	EB-RFA-Stent group	Stent group	<i>p</i> -value
Technical success, <i>n</i> (%)	9 (100)	9 (100)	–
Total serum bilirubin (mg/dl)*	$3.8 \pm 2.6$	$2.8 \pm 2.8$	0.492
Direct serum bilirubin (mg/dl)*	$2.8 \pm 2.0$	$1.4 \pm 1.3$	0.130
Stricture diameter (mm)	$2.3 \pm 1.1$	$1.1 \pm 0.9$	0.011
Post-procedural diameter (mm)	$7.9 \pm 2.1$	$5.5 \pm 1.6$	0.020
Duration of stent patency, median (95% CI) (days)	$163.6 \pm 38.0$	$76 \pm 14.4$	0.012
Overall survival	$267.7 \pm 68.5$	$239.6 \pm 55.5$	0.302

All categorical variables are presented as mean  $\pm$  SD (standard deviation).

\*Values at the end of the first week following the procedure regarded as clinical success.

EB-RFA – endobiliary radiofrequency ablation, CI – confidence interval

context, SEMS is accepted as the definitive decompression option for resolving malignant stenosis compared to plastic, covered-metal, and drug-eluting stents [14]. Nevertheless, in the literature, SEMS occlusion rates of up to 50% have been reported within 6–8 months of insertion due to tumoural or non-tumoural (epithelial hyperplasia and/or sludge formation) causes [15,16]. Therefore, alternative management modalities that can prolong stent patency and potentially prolong patient survival were explored. EB-RFA may be a less invasive option to establish stent patency [17]. This relatively novel technique is based on the induction of coagulative necrosis in neighbouring tissues with a thermal effect, and the target is to delay tumour ingrowth and outgrowth. This could prolong the duration of stent patency. RFA can be delivered endoscopically or percutaneously, and previous studies demonstrated the efficacy and safety of these devices with both methods [13,18,19].

In the literature, SEMS was reported to remain patent for periods ranging from 3 to 6 months alone, whereas median stent patency was 4–9 months with the use of the EB-RFA procedure [20,21]. Two types of EB-RFA systems were developed, and most reports are about power-controlled RFA catheters and most are in retrospective nature. In these studies, median stent patency was reported as 4 to 9 months, as mentioned above. There are few studies that were conducted to compare the efficacy and safety of percutaneous EB-RFA and SEMS placement with stent placement alone. In a retrospective study, Cui *et al.* reported there was significantly higher primary stent patency time in the study group ( $p = 0.006$ ) [20]. In another study, in which temperature-controlled ablation systems were used, the median stent patency was reported to be significantly longer in the RFA group than in the control group, similarly to our study ( $p = 0.016$ ) [18]. Wang *et al.* also stated that RFA adjunct to stenting prolongs stent patency. In our study, the mean stent patency was statistically significantly longer in the RFA group than in the control group ( $p = 0.012$ ). Additionally, Cui *et al.* explained differences in outcomes among studies with subgroup analyses. Compared with non-cholangiocarcinoma, cholangiocarcinoma that originates from the bile duct was reported to respond better to EB-RFA [20]. In this context, EB-RFA was primarily chosen before stenting in stenoses of biliary origin. The effect of RFA on overall survival is a more controversial issue, and the results must be interpreted cautiously. Both studies showed no survival benefit in patients with non-resectable malignant biliary obstruction [4,20]. On the other hand, Yiannis *et al.* and Uyanık *et al.* reported

significantly longer overall survival in the ablation group [18,22]. In our study, there was no significant difference in overall survival between EB-RFA combined treatment and stenting alone ( $p = 0.302$ ). This may be because many patients die due to progression of malignant disease, not due to stent obstruction and incomplete tumour ablation, as stated above by Wang *et al.* The effect of endobiliary RFA on survival remains controversial, and prospective studies with aetiological subgroup analyses in larger study groups are needed.

Several complications could be associated with uncontrolled high-temperature power-controlled catheters. The ablation of perihilar MBO in particular is considered to involve a high risk of complications. In the literature, Tal *et al.* and Dolak *et al.* reported various major complications that are thought to be due to uncontrolled high temperature, such as liver infarction and hepatic coma [23,24]. Moreover, Zhou *et al.* reported 2 cases of biliary perforation, one resulting in mortality [25]. On the other hand, the previous prospective randomized study on the endoscopic usage of temperature-controlled ELRA showed that this novel device was safe and there were no unintended thermal injury-related complications in the ablation group [10]. In this study, we used a temperature-controlled EB-RFA system percutaneously, and there were no major complications in either group. The low complication rate in our study may be associated with the newly developed system we used. Control of temperature in the ablation zone offers reduced risk of biliary complications, and in our study there was no statistically significant difference between the 2 groups in terms of cholangitis rate, a minor complication ( $p > 0.05$ ).

This study had some limitations. Firstly, it was designed retrospectively with a limited number of patients. Prospective studies including different aetiologies in more homogeneous and specific patient groups will help to more clearly determine the effect of endobiliary ablation.

## Conclusions

We demonstrated that a temperature-controlled EB-RFA system is a safe and feasible palliative treatment option for prolonging stent patency in inoperable malignant biliary obstruction.

## Conflicts of interest

The authors report no conflict of interest.

## References

1. Singh A, Siddiqui UD. The role of endoscopy in the diagnosis and management of cholangiocarcinoma. *J Clin Gastroenterol* 2015; 49: 725-737.
2. Sawas T, Al Halabi S, Parsi MA, et al. Self-expandable metal stents versus plastic stents for malignant biliary obstruction: a meta-analysis. *Gastrointest Endosc* 2015; 82: 256-267.e7.

3. Loew BJ, Howell DA, Sanders MK, et al. Comparative performance of uncoated, self-expanding metal biliary stents of different designs in 2 diameters: final results of an international multicenter, randomized, controlled trial. *Gastrointest Endosc* 2009; 70: 445-453.
4. Wang J, Zhao L, Zhou C, et al. Percutaneous intraductal radiofrequency ablation combined with biliary stent placement for nonresectable malignant biliary obstruction improves stent patency but not survival. *Medicine (Baltimore)* 2016; 95: e3329.
5. Steel AW, Postgate AJ, Khorsandi S, et al. Endoscopically applied radiofrequency ablation appears to be safe in the treatment of malignant biliary obstruction. *Gastrointest Endosc* 2011; 73: 149-153.
6. Figueroa-Barojas P, Bakhru MR, Habib NA, et al. Safety and efficacy of radiofrequency ablation in the management of unresectable bile duct and pancreatic cancer: a novel palliation technique. *J Oncol* 2013; 2013: 910897.
7. Cho JH, Lee KH, Kim JM, et al. S. Safety and effectiveness of endobiliary radiofrequency ablation according to the different power and target temperature in a swine model. *J Gastroenterol Hepatol* 2017; 32: 521-526.
8. Khorsandi S, Zacharoulis D, Vavra P, et al. The modern use of radiofrequency energy in surgery, endoscopy and interventional radiology. *Eur Surg* 2008; 40: 204-210.
9. Kato A, Shimizu H, Ohtsuka M, et al. Surgical resection after downsizing chemotherapy for initially unresectable locally advanced biliary tract cancer: a retrospective single-center study. *Ann Surg Oncol* 2013; 20: 318-324.
10. Kang H, Chung MJ, Cho IR, et al. Efficacy and safety of palliative endobiliary radiofrequency ablation using a novel temperature-controlled catheter for malignant biliary stricture: a single-center prospective randomized phase II TRIAL. *Surg Endosc* 2021; 35: 63-73.
11. Sacks D, McClenny TE, Cardella JF, et al. Society of interventional radiology clinical practice guidelines. *J Vasc Interv Radiol* 2003; 14: 199-202.
12. El-Diwany R, Pawlik TM, Ejaz A. Intrahepatic cholangiocarcinoma. *Surg Oncol Clin N Am* 2019; 28: 587-599.
13. McKinley SK, Chawla A, Ferrone CR. Inoperable biliary tract and primary liver tumors: palliative treatment options. *Surg Oncol Clin N Am* 2019; 28: 745-762.
14. Sharaiha RZ, Natov N, Glockenberg KS, et al. Comparison of metal stenting with radiofrequency ablation versus stenting alone for treating malignant biliary strictures: is there an added benefit? *Dig Dis Sci* 2014; 59: 3099-3102.
15. Kim HS, Lee DK, Kim HG, et al. Features of malignant biliary obstruction affecting the patency of metallic stents: a multicenter study. *Gastrointest Endosc* 2002; 55: 359-365.
16. Maire F, Hammel P, Ponsot P, et al. Long-term outcome of biliary and duodenal stents in palliative treatment of patients with unresectable adenocarcinoma of the head of pancreas. *Am J Gastroenterol* 2006; 101: 735-742.
17. Li TF, Huang GH, Li Z, et al. Percutaneous transhepatic cholangiography and intraductal radiofrequency ablation combined with biliary stent placement for malignant biliary obstruction. *J Vasc Interv Radiol* 2015; 26: 715-721.
18. Uyanık SA, Ögürlü U, Çevik H, et al. Percutaneous endobiliary ablation of malignant biliary strictures with a novel temperature-controlled radiofrequency ablation device. *Diagn Interv Radiol* 2021; 27: 102-108.
19. Yildirim G, Karakas HM. Endobiliary radiofrequency ablation in malignant biliary strictures: nonrandomized prospective cohort study. *Türkiye Klinikleri J Med Sci* 2021; 41: 280-288.
20. Cui W, Wang Y, Fan W, et al. Comparison of intraluminal radiofrequency ablation and stents vs. stents alone in the management of malignant biliary obstruction. *Int J Hyperthermia* 2017; 33: 853-861.
21. Xia N, Gong J, Lu J, et al. Percutaneous intraductal radiofrequency ablation for treatment of biliary stent occlusion: a preliminary result. *World J Gastroenterol* 2017; 23: 1851-1856.
22. Kallis Y, Phillips N, Steel A, et al. Analysis of endoscopic radiofrequency ablation of biliary malignant strictures in pancreatic cancer suggests potential survival benefit. *Dig Dis Sci* 2015; 60: 3449-3455.
23. Tal AO, Vermehren J, Friedrich-Rust M, et al. Intraductal endoscopic radiofrequency ablation for the treatment of hilar non-resectable malignant bile duct obstruction. *World J Gastrointest Endosc* 2014; 6: 13-19.
24. Dolak W, Schreiber F, Schwaighofer H, et al. Endoscopic radiofrequency ablation for malignant biliary obstruction: a nationwide retrospective study of 84 consecutive applications. *Surg Endosc* 2014; 28: 854-860.
25. Zhou C, Wei B, Gao K. Biliary tract perforation following percutaneous endobiliary radiofrequency ablation: a report of two cases. *Oncol Lett* 2016; 11: 3813-3816.