

Original paper

Can diffusion-weighted imaging be used in the examination of peritoneal fluids?

Zeynep Keskin^{A,B,C,D,E,F}

Konya City Hospital, Konya, Turkey

Abstract

Purpose: The aetiology of free fluid detected in the abdomen can be investigated with magnetic resonance imaging (MRI). The aim of this study is to investigate the effectiveness of diffusion-weighted images (DWI) and apparent diffusion coefficient (ADC) values in the evaluation of abdominopelvic fluids.

Material and methods: Patients with abdominopelvic fluid detected on MRI of the lower abdomen were included in this retrospective, single-centre study. Paracentesis and fluid analysis was performed in these patients. The average ADC values in fluids were measured by a radiologist. A cut-off value was determined, and the specificity, sensitivity, negative predictive value (NPV), and positive predictive values (PPV) were calculated. Intra-observer agreement was investigated.

Results: The study comprised 41 (33 female) patients, and their mean age was 48 ± 4.02 years. The ADC values in infective fluids were significantly higher than in non-infective fluids ($p < 0.001$). The cut-off value used was $2.95 \times 10^{-3} \text{ mm}^2/\text{s}$. According to this threshold value, sensitivity in distinguishing non-infective from infective fluids was 88%, specificity was 93.8%, PPV was 95.7%, and NPV was 83.3%. Intra-observer agreement was strong in ADC values ($\kappa = 0.699$) ($p < 0.001$).

Conclusions: We concluded that the ADC value is a non-invasive, reliable, reproducible imaging parameter that can be useful in the evaluation and characterization of abdominal fluids.

Key words: DWI, ADC, MRI, peritoneal fluid, malignity, benignity.

Introduction

Ascites is the abnormal accumulation of fluid in the peritoneal cavity. Normally, there is a small amount ($< 50 \text{ ml}$) of high protein (4 g/dl) fluid in the peritoneal cavity, as in other serous spaces. The accumulation of pathological amounts of fluid in the peritoneal cavity is called ascites, and this fluid is called ascites fluid [1]. Ascites is the most common complication of cirrhosis and the most common cause of acid build up in liver disease and cirrhosis, especially in those that are alcohol related [2]. This fluid accumulation can be due to various aetiological reasons, depending on the differences in its pathogenesis. According

to Starling's hypothesis, there are 2 important factors in ascites formation, comprising plasma colloid osmotic pressure and portal venous pressure, and fluid exchange between blood and tissue spaces is controlled by the balance between them [3]. When ascites is detected in a patient, differential diagnosis is important because the treatment is determined according to the nature of the fluid. The diagnosis is made in line with the clinical, biochemical, and pathological findings. Generally, the first step is the biochemical analysis of the fluid, which is taken via paracentesis, to distinguish the effusion from exudate and transudate [4]. It can be used for the same purpose in the Light Criteria after determination of the protein and lac-

Correspondence address:

Zeynep Keskin, Konya City Hospital, Konya, Turkey, e-mail: zkeskin@gmail.com

Authors' contribution:

A Study design · B Data collection · C Statistical analysis · D Data interpretation · E Manuscript preparation · F Literature search · G Funds collection

tate dehydrogenase (LDH) in the blood and abdominal fluid [5]. In such cases, albumin levels in the blood and abdominal fluid can help to differentiate it [6,7]. If it is definitively determined that the fluid is exudate, additional examinations, such as abdominal fluid cytology, Gram staining, and culture, are required to evaluate the regional factors [8]. In addition, some clinical symptoms such as fever, abdominal pain, encephalopathy, gastrointestinal bleeding, leukocytosis, renal failure, or metabolic acidosis were found in these patients. Possible risks of paracentesis can be prevented with a non-invasive imaging method that can be used for such cases. In recent years, magnetic resonance imaging (MRI) has been used to investigate a wide variety of chemical and physical properties of tissues. Diffusion-weighted imaging (DWI) is a functional imaging technique that reflects molecular water movement in biological tissues, which has recently been examined in clinical studies. DWI provides information about the mobility or viscosity of water molecules that differ in normal and abnormal tissue. An apparent diffusion coefficient (ADC) map, which is a mathematical map obtained with different gradients, is interpreted via DWI [9,10]. High ADC values, i.e. normal or increased diffusion conditions, are seen in healthy tissues or benign pathologies. These lesions have large extracellular areas and decreased cell density. Conversely, low ADC values obtained by the restriction of diffusion indicate hypercellularity and cytotoxic oedema or a concentrated content (haemorrhage or high protein content) [11].

The aim of this study was to investigate the effectiveness of DWI and the obtained ADC values in distinguishing the infectious and non-infectious aetiology of abdominopelvic fluids.

Material and methods

Study population

After obtaining approval from the local Ethics Committee (05/03.03.2021), patients who were admitted to our hospital with different complaints between January 2015 and June 2019 and who were found to have abdominopelvic fluid on radiological examination were evaluated. Fifty

participants who underwent paracentesis for the diagnosis of the detected fluid and biochemical-pathological analysis of the fluid were included in the study. Some patients who could not be evaluated or measured due to the partial volume effect, inhomogeneity, or motion artifacts were excluded from the study. The reasons for this were that the abdominopelvic fluid had an anteroposterior thickness of less than 15 mm, or there was only upper abdominal fluid because there was no suitable area for measurement. The fluid with a dense haemorrhagic content was excluded because it disrupted the ADC values (Figure 1). Thus, a total of 41 patients (33 females, 8 males) with abdominopelvic fluid were included in the study. The fluids, taken via the paracentesis method, were delivered to the necessary laboratories for biochemical, microbiological, and cytological examination. With this fluid additional examinations were performed, such as a cytological evaluation, in addition to measurement of the cell count, adenosine deaminase (ADA) level, presence of bilirubin, and amylase level, to determine whether the fluid was infective or not. The tests were administered as part of the routine evaluation process for these patients. Therefore, they were performed at no additional cost. A general consent form was obtained from each of the participants, allowing their findings to be used for research and educational purposes, provided that their identities were kept confidential.

Magnetic resonance imaging protocols

All participants were imaged using a 1.5 T MR (Magnetom Area; Siemens AG Medical Solutions, Forchheim, Germany) device at our Imaging Unit. The examinations were performed with the patient in the supine position, head-first in the device. Abdominopelvic MRI examinations were performed using an 18-channel body coil and were accompanied by respiratory monitoring. During the examination, information was given to the patients regarding the facts about the issues that they must comply with. Sedation was not applied. First, the anatomical images were taken with a coronal and axial T2-weighted single-shot fast spin echo (HASTE; TR/TE1: 200/91 ms; slice thickness: 6 mm; inter-slice spacing: 1 mm; average number of signals: 1; field of view: 400-500 mm²; matrix size: 256 × 256; integrated parallel acquisition technique factor). Later, 3 series, comprising single shot, spin echo, and eco-planar (SS-SE-EP), were performed. Using the DWI method (TR/TE/NEX/eco-planar imaging factor: 4000/98/1/77; sensitizing variables in x, y, and z directions), images were obtained with b values at the level of 50, 400, and 800 s/mm². ADC maps were then constructed from these images. Fat suppression was performed using the spectral saturation inversion recovery (SPIN) technique. MRI examination was performed at 1-mm intervals, a 6-mm thick slice thickness, and 120 × 192 matrix setting. The DWI display time was 3-4 min.




Figure 1. Flow chart of the study

Imaging analysis

Quantitative analysis was performed using the Siemens Workstation syngo.via View Forum (release 3.4-inch system, Erlangen, Germany). The measurements of the ADC values were made by a radiologist who had 15 years of professional experience, and was unaware of the clinical findings. Measurements were made on ADC maps with reference to the T2-weighted images of the patients. The ADC values were measured by the region of interest (ROI). The ROI was standardized to 1 cm², placed in the centre as much as possible to reduce interference with surrounding tissues, and the area was kept wide. The radiologist made 3 separate measurements from different areas of the fluid. Measurements were repeated after 3 weeks for intra-observer evaluation. The mean of these measurements was determined as the average ADC value of the abdominopelvic fluid.

Statistical analysis

Statistical analysis was performed using IBM SPSS Statistics for Windows 25.0 (IBM Corp., Armonk, NY, USA). Data were presented as the mean \pm standard deviation. Analysis of whether the numerical data showed normal distribution was performed using the Kolmogorov-Smirnov test. The differences between the normally distributed groups were investigated using Student's *t*-test. The 2-test was used to calculate the differences between the categorical variables. $P < 0.05$ was considered as statistically significant. Intra-observer agreement in distinguishing between the infected and non-infected fluid according to ADC values was evaluated with the *k* test. ROC curve analysis was performed to distinguish the ADC values of the infective and non-infective abdominopelvic fluids from each other. A potential cut-off value was determined and the specificity, sensitivity, negative predictive value (NPV), and positive predictive values (PPV) were calculated. In the evaluation of the area under the curve, cases with a type 1 error level below 5% were interpreted as having a diagnostic test value that was statistically significant.

Results

A total of 3583 pelvic MRIs obtained in a single tertiary centre with the standard protocol were re-evaluated. Patients who did not have ascites, did not undergo paracentesis, had ascites of haemorrhagic character, had a fluid thickness of less than 15 mm, and whose MRI examinations could not be evaluated as optimal due to artifacts were excluded from the study. Thus, the number of participants included in the study was 41 (Figure 1). The average age of participants was calculated as 48 ± 4.02 years (age range: 18-86 years, 95% CI: 42.04-53.96). Thirty-three of the participants were female and 8 were male. Twenty-one

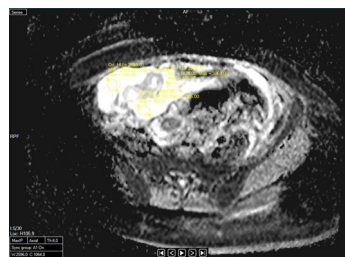


Figure 2. The ADC values of infectious pelvic fluid in a 38-year-old female patient diagnosed with pleural inflammatory disease

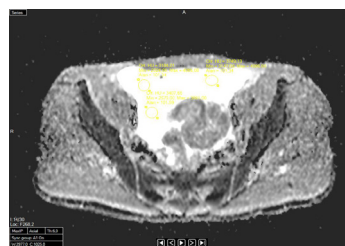


Figure 3. The ADC values in non-infective pelvic fluid in a 62-year-old male patient with pancreatic adenocarcinoma

of the intraabdominal fluids were of malignant processes; 20 of them were due to benign processes, and one of them was due to cardiac failure. A female patient with a diagnosis of lobular breast carcinoma with liver metastases and a male patient with a diagnosis of non-small cell lung cancer were imaged with MRI for intra-abdominal fluid (Figures 2 and 3). Among the participants included in this study, none had a proven diagnosis of tuberculosis, which is a common infection and a cause of increased fluid in the abdomen. The biochemical properties and causes of the detected intra-abdominal fluids are given in Table 1. The biochemical characteristics of the fluids were transudate in 25 cases and exudate in 16 cases. The mean ADC values were $2.89 \pm 0.19 \times 10^{-3}$ mm²/s in transudate fluids and $2.99 \pm 0.21 \times 10^{-3}$ mm²/s in exudate fluids. There was no statistically significant result between biochemical properties and ADC values ($p = 0.052$). Intra-abdominal fluid was transudate in 12 patients with intra-abdominal malignancy and exudate in 9 patients. Of the infective fluids, 12 were exudates and 8 were transudate. The mean ADC values obtained were $2.66 \pm 0.19 \times 10^{-3}$ mm²/s from infective fluids and $3.24 \pm 0.22 \times 10^{-3}$ mm²/s in non-infective fluids. ADC values were higher in non-infectious fluids. There was a significant difference between the groups ($p < 0.001$) (Table 2). The non-infective fluid mean ADC value was $3.02 \pm 0.28 \times 10^{-3}$ mm²/s in females and $3.04 \pm 0.12 \times 10^{-3}$ mm²/s in males. The infective fluid mean ADC value was calculated as $2.62 \pm 0.34 \times 10^{-3}$ mm²/s in females and $2.42 \pm 0.31 \times 10^{-3}$ mm²/s in males. There was no statistical correlation between gender and ADC values in both groups ($p < 0.538$).

The ROC curve analysis obtained by plotting the ADC values planned to be used to differentiate between infective and non-infective fluids showed an AUC of 0.99 (0.96-1; 99% CI; $p < 0.001$). In this analysis, the optimum

Table 1. Causes of development of abdominopelvic fluids

The aetiology of peritoneal fluid	The features of fluid	
	Transudate (21 F, 4 M)	Exudate (12 F, 4 M)
Colon cancer	2	1
Undiagnosed fluid	3	3
Malign epithelial tumour	1	–
Cervix carcinoma	1	1
Cardiac failure	1	–
Renal cell carcinoma	2	1
Crohn disease	1	–
Endometrioma	1	–
Acute pancreatitis	1	1
Cholangiocellular carcinoma	3	–
Metastasis	1	1
Pancreas carcinoma	1	–
Testis carcinoma	–	1
Over carcinoma	2	2
Endometrium ca	–	1
Pelvic inflammatory disease	2	4
Cirrhosis	1	–
Ovarian simple cyst	2	–
Total	25	16

cut-off value for the ADC values in infectious and non-infectious fluids was calculated as $2.95 \times 10^{-3} \text{ mm}^2/\text{s}$ (Figure 4). According to these threshold values, the sensitiv-

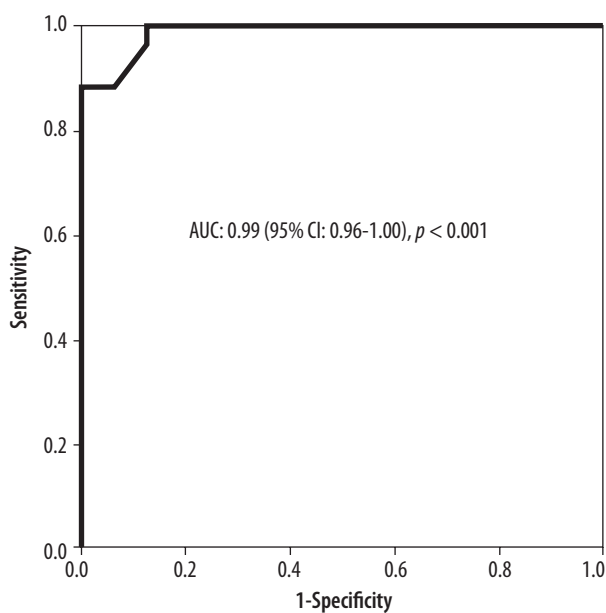


Figure 4. ROC curve for parameters in the discrimination of groups (infectious or non-infectious origin)

Table 2. Analysis of ADC values obtained by DWI of infectious and non-infectious fluids

	Infectious fluids (n = 16)	Non-infectious fluids (n = 25)	p-value
ADC values ($\times 10^{-3} \text{ mm}^2/\text{s}$)	2.66 ± 0.19 (95% CI: 2.56-2.76)	3.24 ± 0.22 (95% CI: 3.15-3.33)	< 0.001

DWI – diffusion-weighted imaging, ADC – apparent diffusion coefficient

ity of the ADC values in distinguishing the non-infective fluids from the infective fluids was 88%, the specificity was 93.8%, the PPV was 95.7%, and the NPV was 83.3% (Figure 5).

The ADC values obtained by the radiologist who performed MRI evaluations and measurements at workstations at different times were as follows: The mean ADC value obtained at the first evaluation was $2.66 \pm 0.2 \times 10^{-3} \text{ mm}^2/\text{s}$ for infectious fluids and $3.24 \pm 0.22 \times 10^{-3} \text{ mm}^2/\text{s}$ for non-infectious fluids. The values obtained in the second evaluation were $2.65 \pm 0.2 \times 10^{-3} \text{ mm}^2/\text{s}$ and $3.23 \pm 0.19 \times 10^{-3} \text{ mm}^2/\text{s}$, respectively. The intra-observer agreement value (κ) in determining the threshold value of the ADC measurements was calculated as 0.699 to evaluate the repeatability and reliability of the measurements (strong agreement, $p < 0.001$).

Discussion

Ascites refers to fluid accumulation in the peritoneal cavity as a general concept. Under normal conditions, there is around 25 ml of protein-rich fluid in the peritoneal cavity. The differential diagnosis of a patient with ascites begins with the analysis of the ascites fluid. Although there are

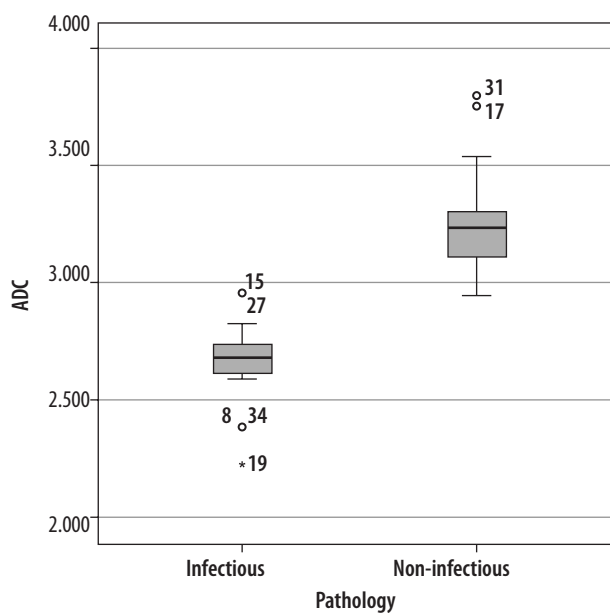


Figure 5. Box charts according to the aetiology of peritoneal fluid

many reasons for this fluid increase, most often it is a decompensation finding that is frequently encountered in the natural course of cirrhosis [12,13]. Complications of ascites can be listed as fluid infections, hepatorenal syndrome, hepatic hydrothorax, and abdominal wall hernias. The frequency of spontaneous acid infections is variable and has been reported as between 3.5-25% [14-17]. Possible risks of paracentesis can be prevented with a noninvasive imaging method that can be used for such patients. These radiological methods include ultrasonography (US), computed tomography (CT), and MRI [18]. In most cases, it is inadequate to characterize fluids by calculating the CT attenuation values, measuring signal intensities on the MRI, or using contrast agents [19,20]. DWI, which can be applied to devices with a magnetic power of 1.5 T or above, is a fast and noninvasive MRI method that does not require the use of contrast agents [21,22]. With the use of fast MRI sequences, such as echo-planar imaging, DWI can be used to image all parts of the body [23,24]. In our imaging centre, DWI is included in the abdominal MRI protocol. DWI measures the random movements of water molecules, while ADC reflects the quantitative value and speed of diffusion impedance of water molecules. The ADC values can be calculated automatically using the software in MRI devices [21,25,26]. The ADC map obtained by DWI has emerged as a new method for characterization of pleural fluid at the molecular level [27]. There are 3 studies in the English language medical literature regarding the use of DWI in pleural fluid analysis [27-29]. In these studies, the ADC values were found to be lower in the exudative fluids than in the transudative fluids. To the best of our knowledge, there have been no other studies conducted to determine the diagnostic value of ADC values in abdominopelvic fluids. In the findings herein, the mean ADC values of the infective fluids were significantly lower than those of the non-infective fluids. Therefore, the hyperintensity of exudate in the DWI images could not be completely attributed to the T2 FLAIR effect. The differences in the ADC values may have been due to the fluid content. Since infective, malignant, and tuberculosis-related fluids are rich in protein content and the number of cells (inflammatory cells, tumour cells, and lymphocytes, respectively). The ADC values in these fluids were found to be low. In the current study, only the ADC values of the fluids were taken into consideration, while a quantitative and qualitative analysis of the DWI was not performed. The ADC threshold value, specificity, sensitivity, NPV, PPV, and diagnostic accuracy ratio were $3/38 \times 10^{-3} \text{ mm}^2/\text{s}$, 85%, 90.6%, 85%, 90.6%, and 88.5% for the first study; $3.6 \times 10^{-3} \text{ mm}^2/\text{s}$, 63%, 71%, 68%, 66%, and 67% for the second study; and $3.51 \times 10^{-3} \text{ mm}^2/\text{s}$, 90.4%, 78%, 86.5%, 83.9%, and 84.9% for the third study [26,28,29]. In the present study, the

ADC threshold value was measured as $2.95 \times 10^{-3} \text{ mm}^2/\text{s}$, and the threshold value was significantly lower than in the other studies. Standing and lying in a fixed position can cause the abdominopelvic fluid to concentrate due to gravity. In this study, the ADC values measured from the lower abdomen and pelvic regions may have been lower due to this concentration.

Lower abdominal and pelvic fluids were included in this research for the reliability of the study because it was observed that the ADC threshold values in the examinations performed in the upper abdomen were similar to the values measured in pleural fluids in other studies. The specificity, sensitivity, NPV, PPV, and diagnostic accuracy rate of the ADC value in the abdominal fluids were similar to those in other studies.

This study had some technical limitations. The first of these was the low signal-to-noise ratio in the echo planar imaging (EPI) sequence obtained with a high b value, resulting in image distortion. Another limitation was that anatomical distortion may have occurred in the EPI sequence due to sensitivity effects [24]. In the study of Mürtz *et al.*, to reduce the effect of this limitation, the ECG-triggered SS-SE-EPI sequence was used in 12 patients to minimize the effect of their heartbeat [30]. As a result, they observed that when the pulse-triggering technique was not used, the accuracy rate of the ADC values measurements of the abdominal organs decreased with DWI. In this study, the pulse triggering technique was not used in the imaging protocol.

In summary, the diagnosis of infective or non-infective abdominal fluids was performed via the combined evaluation of the imaging, laboratory results, and clinical information. Early diagnosis of infective fluid before wall structure occurs may prevent unnecessary invasive treatments. According to the preliminary data, DWI can be useful in these situations. It can be easily included in abdominopelvic examinations because its application is quick and simple with reasonable sensitivity and specificity. DWI offers the radiologist tips for evaluating abdominal fluids in their daily radiological practice.

Conclusions

It was concluded that the ADC value is a noninvasive, reliable, and reproducible imaging parameter that can be useful in the evaluation and characterization of abdominal fluids. The findings of this study should be confirmed in further studies involving larger participants and larger pathologic conditions.

Conflict of interest

The author reports no conflict of interest.

References

1. Berkow R. The Merck Manual. 14th ed. Merck; 1985, p. 619-620.
2. Dooley JS, Lok ASF, Garcia-Tsao G, et al. Sherlock's diseases of the liver and biliary system. 6th ed. Oxford: Blackwell Scientific Publications Ltd; 1981, p. 119-130.
3. Light RW. Pleural effusions. *Med Clin North Am* 2011; 95: 1055-1070.
4. Romero CS, Hernandez L, Brufao RS, et al. Is it meaningful to use biochemical parameters to discriminate between transudative and exudative pleural effusions? *Chest* 2002; 122: 1524-1529.
5. Light RW, MacGregor MI, Luchsinger PC. Pleural diseases. 6th ed. Philadelphia: Lippincott Williams & Wilkins; 2013.
6. Romero CS, Fernandez C, Martin C, et al. Influence of diuretics on the concentration of proteins and other components of pleural transudates in patients with heart failure. *Am J Med* 2001; 110: 680-686.
7. Bielsa S, Porcel JM, Castellote J, et al. Solving the light's criteria misclassification rate of cardiac and hepatic transudates. *Respirology* 2012; 17: 721-726.
8. Spüntrup E, Bücken A, Adam G, et al. Differenzierung seröser und putrider flüssigkeiten in-vitro und in-vivo mit diffusion gewichteter MRT. *Fortschr Röntgenstr* 2001; 173: 65-71.
9. Chan JH, Tsui EY, Luk SH, et al. Diffusion-weighted MR imaging of the liver: distinguishing hepatic abscess from cystic or necrotic tumor. *Abdom Imaging* 2001; 26: 161-165.
10. Muller MF, Prasad P, Siewer B, et al. Abdominal diffusion mapping with use of a whole-body echo-planar system. *Radiology* 1994; 190: 475-483.
11. Gines P, Quintero E, Arroyo V, et al. Compensated cirrhosis: natural history and prognosis. *Hepatology* 1987; 7: 122-128.
12. D'Amico G, Morabito A, Pagliaro L, et al. Survival and prognostic indicators in compensated and decompensated cirrhosis. *Dig Dis Sci* 1986; 31: 468-475.
13. Garcia-Tsao G. Spontaneous bacterial peritonitis: a historical perspective. *J Hepatol* 2004; 41: 522-527.
14. Evans LT, Kim WR, Poterucha JJ, et al. Spontaneous bacterial peritonitis in asymptomatic outpatients with cirrhotic ascites. *Hepatology* 2003; 37: 897-901.
15. Sanyal AJ, Boyer TD, Terrault NA. Zakim & Boyer's Hepatology. 5th ed. Saunders-Elsevier, 2006; 333-347.
16. Uriz J, Cardenas A, Arroyo V. Pathophysiology, diagnosis and treatment of ascites in cirrhosis. *Baillière's Clinical Gastroenterology* 2000; 14: 927-943.
17. McCloud TC, Flower CD. Imaging the pleura: sonography, CT, and MR imaging. *AJR Am J Roentgenol* 1991; 156: 1145-1153.
18. Nandalur KR, Hardie AH, Bollampally SR, et al. Accuracy of computed tomography attenuation values in the characterization of pleural fluid: an ROC study. *Acad Radiol* 2005; 12: 987-991.
19. Davis SD, Henschke CI, Yankelevitz DF, et al. MR imaging of pleural effusions. *J Comput Assist Tomogr* 1990; 14: 192-198.
20. Aube C, Racineux PX, Lebigot J, et al. Diagnosis and quantification of hepatic fibrosis with diffusion weighted MR imaging: preliminary results. *J Radiol* 2004; 85: 301-306.
21. Ikeda K, Saitoh S, Koida I, et al. A multivariate analysis of risk factor for hepatocellular carcinogenesis: a prospective observation of 795 patients with viral and alcoholic cirrhosis. *Hepatology* 1993; 18: 47-53.
22. Poe LB, Manzione JV, Wasenko JJ, et al. Acute internal jugular vein thrombosis associated with pseudoabscess of the retropharyngeal space. *AJNR Am J Neuroradiol* 1995; 16: 892-896.
23. Naganawa S, Kawai H, Fukatsu H, et al. Diffusion weighted imaging of the liver: technical challenges and prospects for the future. *Magn Reson Med Sci* 2005; 4: 175-186.
24. Le Bihan D, Turner R, Douek P, et al. Diffusion MR imaging: clinical applications. *AJR Am J Roentgenol* 1992; 159: 591-599.
25. Güneş B, Kitiş Ö, Çallı C, et al. İntrakranial kistik lezyonlarda difüzyon-ağırlıklı MR görüntüleme. *Ege Tıp Dergisi* 2003, 42: 107-113.
26. Baysal T, Bulut T, Gökirmak M, et al. Diffusion-weighted MR imaging of pleural fluid: differentiation of transudative vs exudative pleural effusions. *Eur Radiol* 2004; 14: 890-896.
27. Inan N, Arslan A, Akansel G, et al. Diffusion-weighted MRI in the characterization of pleural effusions. *Diagn Interv Radiol* 2009; 15: 13-18.
28. Keskin Z, Yeşilbaş M, Alkan E, et al. Differentiation between transudative and exudative pleural effusions by diffusion weighted magnetic resonance imaging. *Iran J Radiol* 2019; 16: e78775.
29. Mürtz P, Flacke S, Träber F, et al. Abdomen: diffusion-weighted MR imaging with pulse triggered single-shot sequences. *Radiology* 2002; 224: 258-264.