



Received: 2016.06.16
Accepted: 2016.09.08
Published: 2017.06.07

Authors' Contribution:

- A** Study Design
- B** Data Collection
- C** Statistical Analysis
- D** Data Interpretation
- E** Manuscript Preparation
- F** Literature Search
- G** Funds Collection

Endovascular Treatment of Renal Arteriovenous Fistula with N-Butyl Cyanoacrylate (NBCA)

Ewa Kuklik^{ABCDEF}, Michał Sojka^{ABCDF}, Klaudia Karska^{BCDEG}, Maciej Szajner^{ABCDEF}

Department of Radiology and Interventional Neuroradiology, Independent Public Hospital No. 4 (SPSK 4), Lublin, Poland

Author's address: Ewa Kuklik, Department of Radiology and Interventional Neuroradiology, Independent Public Hospital No. 4 (SPSK 4), Jaczewskiego 8 Str., 20-954 Lublin, Poland, e-mail: ekuklik5@wp.pl

Summary	
Background:	Renal arteriovenous malformation (RAVM) is a rare disease. The causes of pathological connections between renal arteries may be congenital or iatrogenic – mainly as a consequence of a biopsy or due to renal carcinomas and postinflammatory changes. Computed tomography, ultrasound Doppler and angiography are the main diagnostic tools used for the detection of RAVMs.
Case Report:	The aim of this study is to present a case of endovascular treatment of RAVM with a mixture of NBCA and lipiodol. A 29-year-old woman was suffering from drug-resistant hypertension secondary to RAVM. The malformation was embolized using NBCA mixed with lipiodol. The postoperative course was uneventful. A follow-up angio-CT, performed 3 months and one year after the procedure, showed a complete occlusion of the RAVM.
Conclusions:	NBCA can be used alone to embolize RAVMs. Procedures involving a combination of NBCA and lipiodol are difficult and should be performed by experienced specialists.
MeSH Keywords:	Aneurysm • Arteriovenous Malformations • Embolization, Therapeutic • Embucrilate
PDF file:	http://www.polradiol.com/abstract/index/idArt/900106

Background

Renal arteriovenous malformation (RAVM) is a rare disease. On post-mortem histopathological examinations, RAVMs appear with an incidence of around 0.04% [1]. They are found more often in females than in males and are more common in the right kidney than in the left kidney. The causes of pathological connections between renal arteries may be congenital or iatrogenic – mainly as a consequence of a biopsy or due to renal carcinomas and postinflammatory changes. RAVMs may cause heart failure and hemorrhage following rupture of the malformation. Computed tomography, ultrasound Doppler and angiography are the main diagnostic tools used for the detection of RAVMs. DSA (digital subtraction angiography) of the renal arteries can precisely determine the location, renal blood supply and hemodynamic changes, which helps make appropriate therapeutic decisions. For this reason, angiography is regarded as the gold standard for the diagnosis of this type of malformation.

The aim of our work is to present a case of endovascular treatment of RAVM accompanied by an aneurysm with the

use of NBCA mixed with lipiodol. Based on the available literature, this method has been used sparsely.

Case Report

A 29-year-old woman with drug-resistant hypertension, 150/110 mmHg, was admitted to the Department of Vascular Surgery for an elective angiography of RAVM, which was previously diagnosed on an ultrasound Doppler examination. Angiography showed an expanded, extended and tortuous dorsal branch of the right renal artery, which supplied around 5% of the renal parenchyma. Additionally, an aneurysm (21 mm) appeared in the proximity of the arteriovenous fistula (Figure 1). An accelerated blood flow in the fistula was noted (Figure 2). The remaining part of right kidney was supplied by regular branches of renal arteries. Based on DSA and following a cardiological consultation, the patient was qualified for endovascular treatment. The aim of the procedure was to close the fistula of the right renal artery branch. The risk of deactivating the right renal parenchyma was estimated to be 5%.

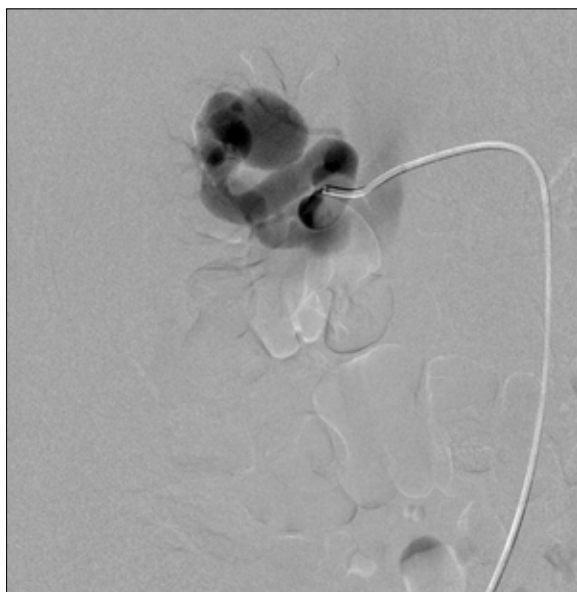


Figure 1. Angiography of the right renal artery dorsal branch provided before the procedure showing the fistula with the aneurysm. Arterial phase.

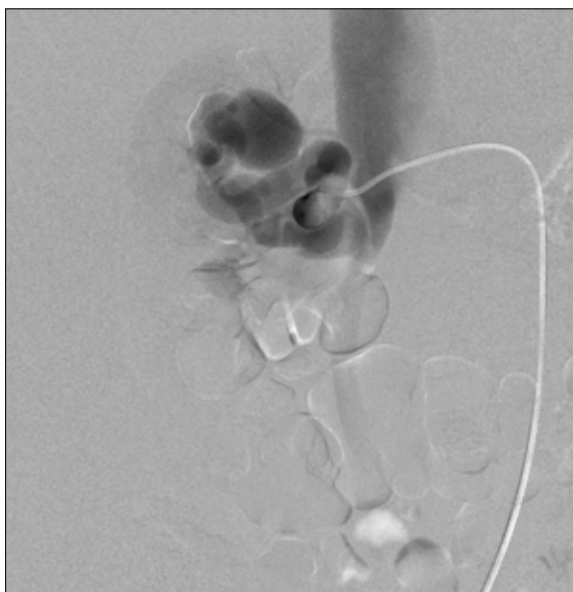

Figure 2. Angiography of the right renal artery dorsal branch provided before the procedure showing the fistula with an aneurysm. Arterial phase tissue phase.

The procedure was performed by puncturing the right femoral artery under local anesthesia using the Seldinger technique. Aortography was performed using a pig-tail diagnostic catheter. Angiography showed an elongated, expanded renal artery branch with an aneurysm (21 mm in diameter). The artery supplied 20% of the right renal parenchyma. In the next stage, a guiding catheter (Envoy 5 F) was placed in the right renal artery and then a micro-catheter (Progreat, Terumo) was introduced selectively into the tortuous branch. Then, NBCA mixed with lipiodol at a concentration of 60% was injected into the malformation. A control angiography showed a complete occlusion of both the aneurysm and the fistula. Twenty percent of the renal parenchyma was excluded. The perioperative period was without complications. Dexamethasone at a dose of 8 mg was recommended for the subsequent 4 days after the intervention. The patient was discharged after 5 days of hospitalization with a recommendation to perform a follow-up angio-CT after 3 months and after one year. A follow-up angiography confirmed an effective exclusion of both the aneurysm and the fistula (Figure 3) [2].

Discussion

Arteriovenous malformation of the kidney was described for the first time in 1928. Since then, nephrectomy has been regarded as the mainstay of treatment. Endovascular procedures changed the approach to treating malformations. Renal artery embolization is considered as a modern and minimally invasive intervention. Lately, it has become the mainstay of treatment for RAVMs. Despite the advantages of transcatheter embolization, the procedure carries some risks of complications. The risk is much higher when fistulas are high-flow lesions.

Embolization of a renal fistula requires a complete occlusion of the artery feeding the malformation with the aim to save as much of the renal parenchyma as possible. This

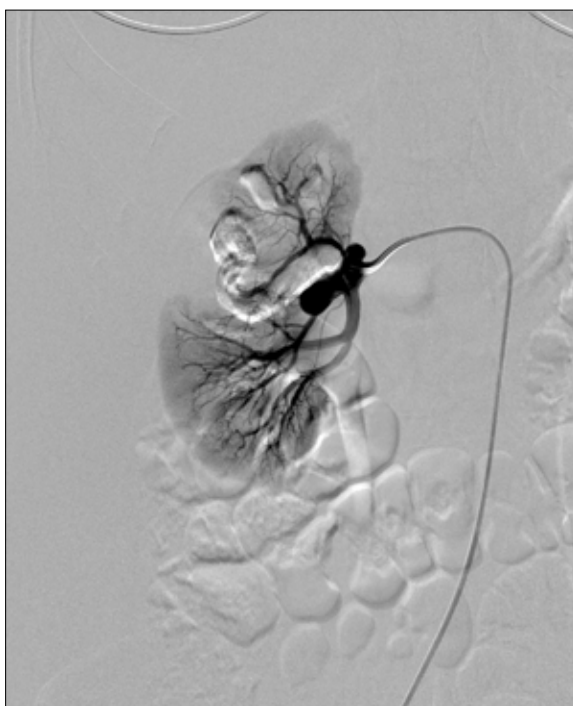


Figure 3. Control angiography of the right renal artery showed a complete occlusion of both the aneurysm and the fistula.

depends mainly on a proper selection of the technique of embolization. There is no standard protocol for RAVM treatment [3].

Nagumo et al. described a successful treatment of a 7-cm renal arteriovenous malformation using coils [4].

Uchikawa et al. described the treatment of renal artery malformations in a group of six patients. They used NBCA as embolization material and coils were additionally

implanted in two patients. In four cases, there were complications as the glue migrated into the venous system. Clinical symptoms of these complications were not observed. In all 6 cases, a therapeutic effect was achieved [5].

Young et al. described the treatment in two pregnant women with RAVM. Embolization was performed with different embolization materials – gel foam and glue. The perioperative period was complicated by a post-embolization syndrome in a patient treated with the gel foam. A therapeutic effect and regression of clinical symptoms were achieved in both cases [1].

Suzuki et al. described Onyx-based treatment in a 65-year-old woman with RAVM. No adverse effects were seen. Clinical symptoms regressed. Five months later, a follow-up angio-CT showed a selective closure of supplying vessels [6].

Ahmed Kamel Abdel-Aal et al. described treatment of an arteriovenous fistula with hydrogel coils. During the intervention, one of the coils migrated into the venous system and got stuck in the left pulmonary artery. The coil was removed by an endovascular procedure through the femoral vein. Subsequently, in order to prevent migration of embolization materials, an occlusion balloon was placed in the renal vein and 300 units of thrombin were injected straight into the malformation. A follow-up angiography

showed occlusion of the fistula. The perioperative period was without complications. A follow-up angio-CT, performed after two months, showed recanalization of the fistula. The patient was treated by embolization with the use of 6-mm AVP 2. During the follow-up period, no complications occurred. A follow-up angio-CT, performed after 4 and 10 months, confirmed an effective treatment [7].

In comparison to the above-described attempts, the method we used seems to be quite effective and relatively safe, if performed by an experienced interventional radiologist. It can achieve an instant occlusion of fistulas or AVMs with accompanying aneurysms, which constitutes a serious clinical problem. Renal aneurysms always carry the risk of peritoneal hemorrhage or serious blood loss and are therefore considered life-threatening. Hence, the method which was used, i.e. a direct injection of NBCA, appeared appropriate for solving this difficult problem.

We would like to draw attention to our case for several reasons. First, because of the aneurysm that accompanied the malformation. Second, because of the fact that a large fistula with a high blood flow was treated solely with NBCA.

Conclusions

NBCA can be used alone to embolize RAVMs. Procedures involving a combination of NBCA and lipiodol are difficult and should be performed by experienced specialists.

References:

1. Chen Y, Liu F, Xing J, Liu R: Treatment of hematuria caused by renal arteriovenous malformation in pregnant patients. *Int J Clin Exp Med*, 2015; 8(2): 3027–29
2. Dangi AD, Kumar R, Kekre NS: Renal arteriovenous malformation with inferior vena caval extension mimicking renal cell carcinoma. *Indian J Urol*, 2014; 30(3): 357–59
3. Juan YH, Lin YC, Sheng TW et al: Application of onyx for renal arteriovenous malformation with first case report of a renal hyperdense striation sign: A CARE-Compliant Article. *Medicine (Baltimore)*, 2015; 94(39): e1658
4. Nagumo Y, Komori H, Rii J et al: [Aneurysmal type renal arteriovenous fistula with giant venous aneurysm, mimicking renal cell carcinoma: A case report.] *Nihon Hinyokika Gakkai Zasshi*. 2015 Apr;106(2): 118–22 [in Japanese]
5. Uchikawa Y, Mori K, Shiigai M et al: Double coaxial microcatheter technique for glue embolization of renal arteriovenous malformations. *Cardiovasc Intervent Radiol*, 2015; 38(5): 1277–83
6. Suzuki R, Gondo A, Jimi K et al: [Two cases of incidentally detected renal arteriovenous fistula over ten years after renal biopsy]. *Nihon Jinzo Gakkai Shi*, 2016; 58(1): 33–37
7. Abdel-Aal AK, Elsabbagh A, Soliman H et al: Percutaneous embolization of a postnephrectomy arteriovenous fistula with intervening pseudoaneurysm using the amplatzer vascular Plug 2. *Vasc Endovascular Surg*, 2014; 48(7–8): 516–21