

Original paper

Can initial apparent diffusion coefficient and tumour volume predict future metastases in treatment-naive patients with laryngeal squamous cell carcinoma

Elif Dilara Topcuoglu^{A,B,C,D,E,F}

Department of Radiology, Umraniye Training and Research Hospital, Umraniye, Istanbul, Turkey

Abstract

Purpose: To evaluate the predictive capability of the apparent diffusion coefficient (ADC) at initial diagnosis in treatment-naive patients with laryngeal squamous cell carcinoma (LSCC) for the development of future metastases.

Material and methods: Magnetic resonance images of patients with pathologically proven non-metastatic, treatment-naive LSCC were retrospectively evaluated. Follow-up positron emission tomography scans were assessed for the scanning of metastases.

Results: A total of 37 patients (32 males and 5 females) with a mean age of 62.8 ± 8.9 years were enrolled. Mean tumour volume and ADC were $4.8 \pm 62 \text{ cm}^3$ and $0.72 \pm 0.51 \times 10^{-3} \text{ mm}^2/\text{s}$, respectively. Six local and 8 distant metastases were detected in a mean follow-up period of 17.5 ± 10.2 months. A significant association between ADC and the presence distant metastases ($p = 0.046$) and local metastases ($p = 0.042$) was found. The difference in mean ADC values between future metastatic and non-metastatic initial tumours was significant ($p = 0.017$).

Conclusions: Pre-treatment ADC values and volume of the initial tumour might provide early information about the development of future metastases in patients with LSCC in this series.

Key words: ADC, MR, DWI, laryngeal carcinoma, neck MR.

Introduction

The current treatment outcomes for laryngeal squamous cell carcinoma (LSCC) remain moderate, and the 5-year survival rates are dependent on the anatomical location and the tumour-node-metastasis (TNM) staging score system [1]. Different types of therapy have improved outcomes, but distant metastases (DM) constitute a challenge in terms of prognosis [2]. Local metastases (LM) in lymph nodes and DM can develop after the curative first-line treatments, even if they were not present at initial diagnosis [3]. Therefore, oncologists want to know the metastatic potential of the initial tumour at diagnosis. While multi-

ple genetic tumour biomarkers are being investigated for this purpose [4-6], advanced magnetic resonance (MR) techniques such as diffusion-weighted imaging (DWI) and apparent diffusion coefficient (ADC) maps may have the potential to predict LM and DM. Pre-treatment ADC and ADC alterations after the treatment have been shown to be correlated with the final response to the therapies, in previous papers [7-9].

The aim of this study was to evaluate the predictive value of ADC at initial diagnosis in treatment-naive patients with LSCC, for the development of future local and distant metastases.

Correspondence address:

Elif Dilara Topcuoglu, MD, Department of Radiology, Umraniye Training and Research Hospital, Umraniye 34764, Istanbul, Turkey, phone: +905056706026, fax: +902165784800, e-mail: elifdilaratopcuoglu@gmail.com

Authors' contribution:

A Study design · B Data collection · C Statistical analysis · D Data interpretation · E Manuscript preparation · F Literature search · G Funds collection

Material and methods

Patient population

The local Ethics Committee approved this single-centre study and waived informed consent. Between October 2016 and January 2022, the hospital's picture archiving and communication system (PACS) was retrospectively evaluated to identify treatment-naïve adult patients with LSCC and MR examination including DWI. Inclusion criteria consisted of patients having biopsy-proven non-metastatic LSCC without previous treatment and planned curative surgical excision ± chemotherapy or chemotherapy ± radiotherapy. Patients without pathological diagnosis and follow-up imaging, patients with previous history of chemo-radiotherapy, patients with local lymph node or distant metastases at the time of the diagnosis, and patients having DWI with excessive artifacts that precluded drawing a region of interest (ROI) were excluded. The presence of LM and DM on follow-up was assessed by positron emission tomography (PET). LM means recurrence of the initial tumour at the neck lymph nodes after the treatment. DM means spread of the initial tumour to distant organs or distant lymph nodes.

MR imaging examinations

All MR examinations were performed by a 1.5 T MR system (Signa HDxt, GE Healthcare, Milwaukee, WI) with a 12-channel head-and-neck coil. The protocol included T1-weighted spin-echo (SE) before and after intravenous gadolinium-based contrast agent (repetition time ms/echo time ms, 683/10) and echo planar imaging (EPI)-DWI with TR/TE: 4571/70.5 ms; inversion time 160 ms, averages: 3; acquisition time ranged between 235 and 314 s; flip-angle: 90°; matrix size: 256 × 256, 21-28 slices. DWI images were obtained before the injection of gadolinium. ADC values were measured using 3 *b*-values (0, 50, and 800 s/mm²) (Table 1).

Table 1. Technical MR imaging parameters

Parameter	Value
Sequence	DWI
Plane	Axial
TR/TE (ms)	4571/70.5
Averages	3
Acquisition time (s)	235-314
Flip angle (°)	90
Matrix size	256 × 256
Slice thickness (mm)	5
<i>b</i> -values	0, 50, 800
Number of slices	21-28

In recent years, there have been indications for use in laryngeal cancer with *b*-values of 50 and 1000 [9-11]. On the other hand, it is worth noting that there are also studies in the literature that use *b*-values of 0 and 800 [12,13]. In this study, *b*-values 0, 50, and 800 were used due to its retrospective nature.

Image analysis

Delineation of the tumours was performed manually by 2 radiologists with 7 and 11 years of experience in head and neck radiology. Delineation was first made on post-contrast T1-weighted axial images and then on corresponding ADC maps (Figure 1). Only the solid tumour area, excluding cystic-necrotic components, was selected for analysis, and ADC calculations were made by 2 radiologists blinded to each other. ROIs were hand-drawn freely on the solid component of the tumour (Figure 1).

Statistical analysis

The relation between the presence of metastases and age, sex, ADC, initial primary tumour T stage, tumour localisation and volume were evaluated by univariate analysis and Student's *t*-test. The inter-observer agreement for ADC measurements was assessed by intra-class correlation coefficient (ICC). An ICC > 0.75 indicates good agreement [14]. As previous studies emphasised, metastasis-free survival analysis regarding ADC < 0.7 × 10⁻³ mm²/s versus ADC ≥ 0.7 × 10⁻³ mm²/s was also assessed [15]. *P*-values < 0.05 were considered statistically significant. IBM SPSS Statistics, v. 21 for Windows (Armonk, NY) was used for all statistical analyses.

Results

A total of 37 patients (32 males and 5 females) with a mean age of 62.8 ± 8.9 years (range 45 to 88 years) met the inclusion criteria and were enrolled in this study. Mean tumour volume and ADC were 4.8 ± 6.2 cm³ and 0.72 ± 0.51 × 10⁻³ mm²/s (range 0.10 to 1.89), respectively. T stages of the tumours before treatment were T1 (*n* = 5), T2 (*n* = 15), T3 (*n* = 11), and T4a (*n* = 6). Sixteen local lymph node and 8 distant metastases were detected on PET scans in a mean follow-up period of 17.5 ± 10.2 months. Both DM and LM were developed in 6 patients. A significant association between initial ADC and the presence of future distant metastases (*p* = 0.046; 95% confidence interval [CI] of the difference between -0.46 and 0.34) and future local metastases (*p* = 0.042; 95% CI of the difference between -0.71 and -0.13) was found. Mean ADC of the initial tumours that would develop distant and local metastases on follow-up, were 0.58 ± 0.23 × 10⁻³ mm²/s and 0.55 ± 0.34 × 10⁻³ mm²/s, respectively. The mean ADC of the initial tumours that would not develop distant or local metastases on follow-up

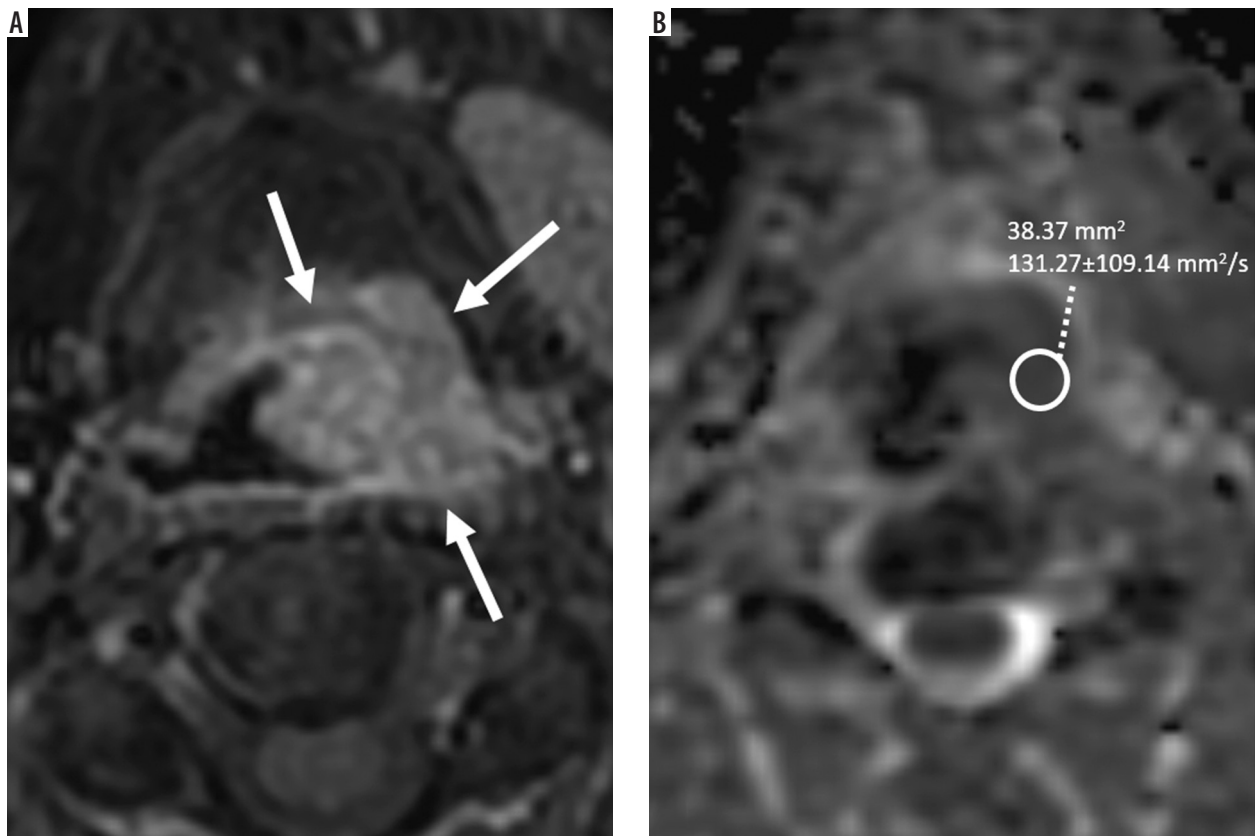


Figure 1. Post-contrast enhanced T1-weighted fat-suppressed image on axial plane (A) shows supraglottic tumour (arrows) obstructing left piriform sinus in a 57-year-old man. Axial plane apparent diffusion coefficient (ADC) map (B) demonstrates diffusion restriction and low ADC value on the corresponding tumour region

Table 2. The association between patient demographics, ADC, tumour variables, and the presence of metastasis.

Variables	Metastasis positive (n = 18)	Metastasis negative (n = 19)	p-value (difference between metastasis+ and metastasis- cases)
Age (years, mean)	63.6 ± 9.5	61.8 ± 8.6	0.557
Gender (male/female)	15/3	18/1	0.198
ADC (mm ² /s, mean)	0.57 ± 0.32	0.94 ± 0.67	0.017
Tumour location			
Supraglottic	7	2	0.292
Glottic	11	16	
Infraglottic	–	1	
Tumour volume (cm ³ , mean)	8.2 ± 7.2	1.8 ± 2.5	< 0.001
T stage			
T1	1	4	0.441
T2	7	8	
T3	6	5	
T4a	4	2	

was $0.94 \pm 0.67 \times 10^{-3} \text{ mm}^2/\text{s}$. The difference of mean ADC values between future metastatic ($0.57 \pm 0.32 \times 10^{-3} \text{ mm}^2/\text{s}$) and non-metastatic ($0.94 \pm 0.67 \times 10^{-3} \text{ mm}^2/\text{s}$) initial tumours was significant ($p = 0.017$) (Table 2, Figure 2). When the relationship between the patient demographics, tumour variables, and the status of metastases were as-

essed, besides ADC, only the tumour volume was found to be significantly associated with the presence of metastases in this series ($p < 0.001$) (Table 2). The inter-observer agreement was high, as ICC = 0.91 [95% CI: 0.86-0.95]. Metastasis-free survival curves according to ADC are shown in Figure 3.

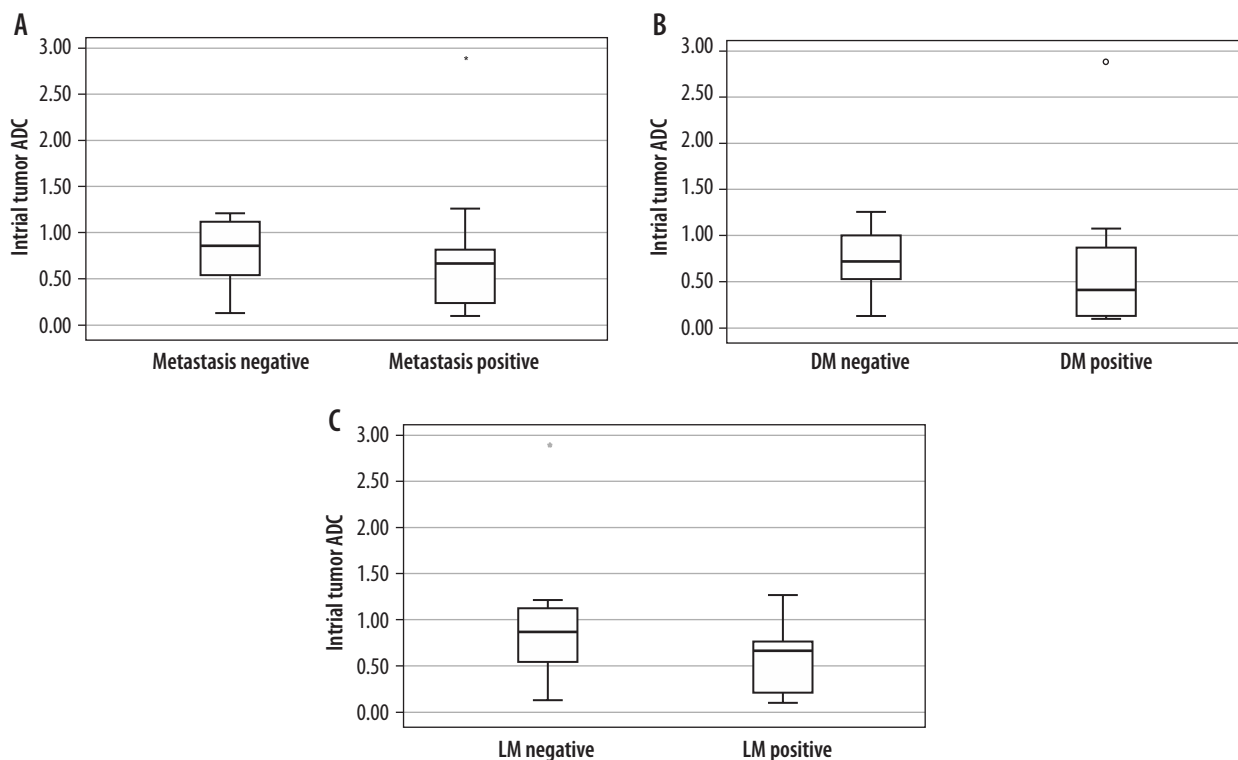


Figure 2. Box plots showing initial tumour apparent diffusion coefficient (ADC) regarding patients with or without metastasis (A), patients with or without distant metastasis (DM) (B), and patients with or without local metastasis (LM) (C). Each box shows median (as line)

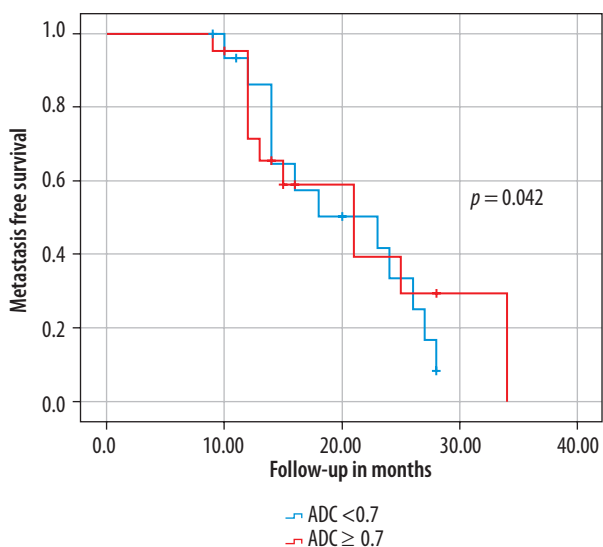


Figure 3. Metastasis-free survival curves according to apparent diffusion coefficient (ADC). Metastasis-free survival was significantly better for patients with initial ADC ≥ 0.7 compared to ADC < 0.7

Discussion

The current study demonstrated that pre-treatment ADC values could be used to predict future local or distant metastases in patients with treatment-naive LSCC. In other words, the metastatic potential of the initial LSCC at diagnosis might be anticipated via ADC maps. Driessen *et al.* [12] found the ADC of the laryngeal or hypopharyngeal

SCC ranging between 0.92 and $1.30 \times 10^{-3} \text{ mm}^2/\text{s}$ in their study involving 16 patients. Although the ADC of the tumours in this series also varied widely, we have demonstrated that the mean ADC values of the future metastatic LSCCs showed a significant difference to those with no future metastases. Similarly to our findings, Brenet *et al.* [15] stated that an initial ADC below 0.7 was significantly more common in patients with residual head and neck (HN) SCC after chemoradiotherapy. They found an mean initial ADC of the residual tumours of $0.56 \pm 0.11 \times 10^{-3} \text{ mm}^2/\text{s}$. Parallely, we have found a mean initial ADC of future distant and local metastatic tumours of $0.58 \pm 0.23 \times 10^{-3} \text{ mm}^2/\text{s}$ and $0.55 \pm 0.34 \times 10^{-3} \text{ mm}^2/\text{s}$, respectively. They also highlighted that ADC elevation at 3-month follow-up MR lower than 0.7 was associated with disease progression or recurrence. Initial ADC < 0.7 ($n = 14$) was more frequent than ADC ≥ 0.7 ($n = 4$) in patients with future metastatic LSCC in this series, and metastasis-free survival was significantly better for patients with initial ADC ≥ 0.7 compared to ADC < 0.7 (Figure 3). Some authors stated that lower ADC of initial HN tumours significantly correlated with the persistent or recurrent HNSCC [16]. In contrast to our results, King *et al.* [17] stated that initial ADC showed no correlation with local failure in patients with HNSCC. Although they found the mean ADC of the tumours with local treatment failure to be lower than those with local control ($1.45 \pm 0.27 \times 10^{-3} \text{ mm}^2/\text{s}$ versus $1.62 \pm 0.29 \times 10^{-3} \text{ mm}^2/\text{s}$, respectively), this difference was not significant. This discrepancy

of results might be due to the heterogeneous sample of their study including primary tumour sites of the oral cavity, oropharynx, hypopharynx, larynx, nasal cavity, and maxillary sinus. Conversely, the current study consisted of patients with only LSCC. Lombardi *et al.* [18] showed that pre-treatment ADC of patients with local control for HNSCC was lower than that of patients with persistent or recurrent disease. Their study again harboured a heterogeneous tumour group of 47 patients with HNSCC. In their study, 42 patients had nasopharyngeal and oropharyngeal carcinomas, 5 hypopharyngeal carcinomas, and there was no laryngeal SCC. Furthermore, in contrast to our ROI drawing, they selected the ROI for the whole tumour region including cystic/necrotic components.

Several papers have shown the utilisation of ADC changes before and during, or before and after, chemoradiotherapy to anticipate local tumour recurrence in HN cancers [19-23]. However, those studies contained mostly extra-laryngeal SCCs (including oropharyngeal, hypopharyngeal, nasopharyngeal, paranasal sinuses, oral cavity tumours, and metastatic neck lymph nodes), and the data of ADC measurements originated from this large heterogeneous primary tumour location. Tomita *et al.* [24] demonstrated a deep learning method for outcome prediction in patients with laryngeal and hypopharyngeal cancers, and they found that a lower intratreatment DWI signal was significantly associated with better 2-year progression-free survival. They used a deep learning approach to eliminate the potential variabilities in ADC calculations including the shape and site of the ROI, and low reproducibility and objectivity. Matoba *et al.* [21] showed that pretreatment ADC was not statistically correlated with the local tumour control, in contrast to the early treatment ADC alterations. Nevertheless, all those papers emphasised, and aimed to predict, local tumour control with ADC measurements. Conversely, we aimed to predict the potential future local and distant metastases by calculating the initial tumour ADC, and we demonstrated a significant difference between the ADC of the future metastatic LSCCs

over those with no future metastases. In addition to ADC, pre-treatment tumour volume was the other variable that was significantly associated with the presence of future metastases. Sistonen *et al.* [25] found that tumours larger than 7 cm³ had increased locoregional recurrence, in a retrospective study harbouring 67 patients with oropharyngeal SCC. Similarly, mean tumour volume was 8.2 ± 7.2 cm³ in the metastasis-positive group in this series.

There were several limitations in the current study. Firstly, the retrospective design of the study was the main restriction. Secondly, the patient population was limited, and the follow-up period was relatively short. However, despite the small sample size, the pathology of the tumours were all LSCC and homogeneous compared to the heterogeneous study populations of the previous papers including whole HN tumours. Finally, pathological parameters such as tumour stroma, and cellular or nuclear density of the tumour were not evaluated in this study.

Conclusions

Pretreatment volume and ADC values of the initial tumour showed the ability to predict the development of future local or distant metastases in patients with LSCC in this series. Therefore, diffusion-weighted MR can be used as an imaging modality to differentiate patients with high potential for the development of local and distant metastases.

Disclosures

1. Institutional review board statement: The study was approved by the Institutional Ethics Committee of the Umraniye Training and Research Hospital, with approval number: B.10.1.TKH.4.34.H.GP.0.01/348.
2. Assistance with the article: None.
3. Financial support and sponsorship: None.
4. Conflicts of interest: None.

References

1. Bradford CR, Ferlito A, Devaney KO, et al. Prognostic factors in laryngeal squamous cell carcinoma. *Laryngoscope Invest Otolaryngol* 2020; 5: 74-81.
2. Duprez F, Berwouts D, De Neve W, et al. Distant metastases in head and neck cancer. *Head Neck* 2017; 39: 1733-1743.
3. Alfieri S, Carenzo A, Platini F, et al. Tumor biomarkers for the prediction of distant metastasis in head and neck squamous cell carcinoma. *Cancers (Basel)* 2020; 12: 922. doi: 10.3390/cancers12040922.
4. Pickhard A, Gröber S, Haug AK, et al. Survivin and pAkt as potential prognostic markers in squamous cell carcinoma of the head and neck. *Oral Surg Oral Med Oral Pathol Oral Radiol* 2014; 117: 733-742.
5. Zhuo X, Luo H, Chang A, et al. Is overexpression of TWIST, a transcriptional factor, a prognostic biomarker of head and neck carcinoma? Evidence from fifteen studies. *Sci Rep* 2015; 5: 18073. doi: 10.1038/srep18073.
6. Rodrigo JP, Martinez P, Allonca E, et al. Immunohistochemical markers of distant metastasis in laryngeal and hypopharyngeal squamous cell carcinomas. *Clin Exp Metastasis* 2014; 31: 317-325.
7. Hamstra DA, Lee KC, Moffat BA, et al. Diffusion magnetic resonance imaging: an imaging treatment response biomarker to chemoradiotherapy in a mouse model of squamous cell cancer of the head and neck. *Transl Oncol* 2008; 1: 187-194.
8. Koh DM, Collins DJ. Diffusion weighted MRI in the body: applications and challenges in oncology. *Am J Roentgenol* 2007; 188: 1622-1635.
9. Vandecaveye V, Dirix P, De Keyzer F, et al. Predictive value of diffusion-weighted magnetic resonance imaging during chemoradio-

- therapy for head and neck squamous cell carcinoma. *Eur Radiol* 2010; 20: 1703-1714.
10. Zhang SC, Zhou SH, Shang DS, et al. The diagnostic role of diffusion-weighted magnetic resonance imaging in hypopharyngeal carcinoma. *Oncol Lett* 2018; 15: 5533-5544.
 11. Roushdy MMM, Elsherif MMR, Kayed EMS, et al. Does diffusion magnetic resonance imaging (dwi) has role in irradiated laryngeal carcinoma? *Indian J Otolaryngol Head Neck Surg* 2022; 74 (Suppl 3): 6339-6346.
 12. Driessen JP, Caldas-Magalhaes J, Janssen LM, et al. Diffusion-weighted MR imaging in laryngeal and hypopharyngeal carcinoma: association between apparent diffusion coefficient and histologic findings. *Radiology* 2014; 272: 456-463.
 13. Dai YL, King AD. State of the art MRI in head and neck cancer. *Clin Radiol* 2018; 73: 45-59.
 14. Portney LG, Watkins MP. *Foundations of clinical research: applications to practice*. New Jersey: Prentice Hall; 2000.
 15. Brenet E, Barbe C, Hoeffel C, et al. Predictive value of early post-treatment diffusion-weighted MRI for recurrence or tumor progression of head and neck squamous cell carcinoma treated with chemoradiotherapy. *Cancers (Basel)* 2020; 12: 1234. doi: 10.3390/cancers12051234.
 16. Vandecaveye V, De Keyzer F, Nuyts S, et al. Detection of head and neck squamous cell carcinoma with diffusion weighted MRI after (chemo)radiotherapy: correlation between radiologic and histopathologic findings. *Int J Radiat Oncol Biol Phys* 2007; 67: 960-971.
 17. King AD, Chow KK, Yu KH, et al. Head and neck squamous cell carcinoma: diagnostic performance of diffusion-weighted MR imaging for the prediction of treatment response. *Radiology* 2013; 266: 531-538.
 18. Lombardi M, Cascone T, Guenzi E, et al. Predictive value of pre-treatment apparent diffusion coefficient (ADC) in radio-chemotherapy treated head and neck squamous cell carcinoma. *Radiol Med* 2017; 122: 345-352.
 19. Hatakenaka M, Nakamura K, Yabuuchi H, et al. Pretreatment apparent diffusion coefficient of the primary lesion correlates with local failure in head-and-neck cancer treated with chemoradiotherapy or radiotherapy. *Int J Radiat Oncol Biol Phys* 2011; 81: 339-345.
 20. Hatakenaka M, Shioyama Y, Nakamura K, et al. Apparent diffusion coefficient calculated with relatively high b-values correlates with local failure of head and neck squamous cell carcinoma treated with radiotherapy. *AJNR Am J Neuroradiol* 2011; 32: 1904-1910.
 21. Matoba M, Tuji H, Shimode Y, et al. Fractional change in apparent diffusion coefficient as an imaging biomarker for predicting treatment response in head and neck cancer treated with chemoradiotherapy. *AJNR Am J Neuroradiol* 2014; 35: 379-385.
 22. King AD, Mo FK, Yu KH, et al. Squamous cell carcinoma of the head and neck: diffusion-weighted MR imaging for prediction and monitoring of treatment response. *Eur Radiol* 2010; 20: 2213-2220.
 23. Chung SR, Choi YJ, Suh CH, et al. Diffusion-weighted magnetic resonance imaging for predicting response to chemoradiation therapy for head and neck squamous cell carcinoma: a systematic review. *Korean J Radiol* 2019; 20: 649-661.
 24. Tomita H, Kobayashi T, Takaya E, et al. Deep learning approach of diffusion-weighted imaging as an outcome predictor in laryngeal and hypopharyngeal cancer patients with radiotherapy-related curative treatment: a preliminary study. *Eur Radiol* 2022; 32: 5353-5361.
 25. Sistonen HJ, Aro K, Atula T, et al. Prognostic value of apparent diffusion coefficient in oropharyngeal carcinoma. *Clin Neuroradiol* 2021; 31: 1037-1048.